

Severe dermatomyositis presenting as quadriplegia: An unusual sequel in elderly

Amrutha Garikapati¹, Sunil Kumar^{2*}, Parth Godhiwala³, Ayush Somani⁴, Atma Nayak⁵

^{1,3-5}Junior Resident, ²Professor and Head, ¹⁻⁵Dept. of Medicine, Jawaharlal Nehru Medical College, Datta Meghe Institute of Medical Sciences (Deemed to be University), Maharashtra, India

***Corresponding Author: Sunil Kumar**

Email: sunilkumarmed@gmail.com

Abstract

Dermatomyositis, an idiopathic inflammatory myopathy, is one of the rare causes of limb paresis. The characteristic feature is skin involvement which differentiates this from other inflammatory myopathy. Here we report a case of severe dermatomyositis as his Creatine Phosphokinase (CPK) level was 32,000 who presented with weakness in all four limbs without any dermatological signs.

Keywords: Dermatomyositis, Creatinine kinase, Quadriplegia, Elderly.

Introduction

Dermatomyositis is rare condition characterised by insidious onset of progressive symmetrical proximal weakness and autoimmune mediated striated muscle inflammation (myopathy).¹ The average age at diagnosis is middle age, with a prevalence rate of 1 per lakh in the general population. Most often females are affected than male in ratio of 2:1. Diagnosis is mainly clinical on the basis of skin lesions, symmetrical and progressive weakness of proximal groups of muscles, raised muscle enzymes like creatine phosphokinase (CPK) and abnormal clues from biopsy of the involved muscles.² We here report a 65 year old male patient with weakness in all four limbs without any skin lesion with very high CPK level suspicious of dermatomyositis.

Case

A 65-year-old male patient farmer by occupation presented with tenderness in all four limb muscles and difficulty in walking. He was also having difficulty in standing after sitting on the floor as well as difficulty in lifting both the arms above the head. All these symptoms were gradual in onset and progressive since last 4-5 months. There were no history of trauma, fever, breathlessness on exertion and difficulty in eating. He was neither on any medications like corticosteroids for any chronic illness like arthritis, asthma nor on statin therapy for ischemic heart disease. He was non-alcoholic and non smoker.

On physical examination, he was afebrile, pulse was 96/minute, and blood pressure was 130/86 mmhg in right arm supine position. His limb muscles were tender on palpation. There was no organomegaly. On neurological motor examination there was grade 4- power shoulder, elbow and joints in upper limbs, whereas grade 4 at the hip, knee and ankle joints in lower limbs. Tone was normal in all groups of muscles. His deep tendon reflexes were diminished and planters were bilaterally flexors. His higher mental functions and cranial nerves examination were normal. The sensory system examination was normal. There was no fasciculations. Examination of the other systems was normal. His blood investigations revealed Hemoglobin of 12

gm%, White Blood Cells of 7200/cumm, and platelets of 3.5 lakhs/ cumm. His Erythrocyte Sedimentation Rate was 45 mm in 1 hour. His kidney function test, liver function tests, urine routine examination, thyroid function tests and blood glucose were within normal limits. His Creatinine phosphokinase were highly elevated as 32000 IU/L, whereas its normal range is 24 to 190 IU/l. Other muscle enzymes like ALT,AST,LDH and aldolase were normal. His HIV and ANA was negative. His chest X-ray, Electrocardiogram, echocardiography, Computerised Tomography of cervical spine, ultrasound abdomen and pelvis were normal. On electromyography examination of the muscles there was early and complete recruitment with polyphasic and low-amplitude AMP. Muscle biopsy showed scattered degenerative changes, few having eosinophilic while others granular [Fig. 1]. On the basis of raised CPK level, electromyographic findings and muscle biopsy, we kept the possibilities of dermatomyositis and treatment was started in the form of prednisolone 50 mg once a day. There was improvement in muscle tenderness and powers as well as there was fall in the creatinine kinase levels. On follow up, he was doing well on prednisolone 10 mg/ day maintenance therapy.

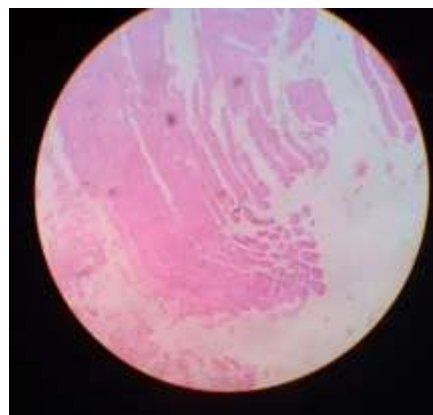


Fig. 1: Muscle biopsy showed skeletal muscle fibers showing scattered degenerative changes consistent with dermatomyositis.

Discussion

Dermatomyositis is one of the major groups of Inflammatory myopathies, others being polymyositis and inclusion body myositis. It usually presents with skin and muscle symptoms. The predominant symptoms are muscle weakness most pronounced in proximal muscle groups - typically in the neck, pelvic, thigh, and shoulder muscles—with a symmetric distribution.^{2,3} The weakness may be severe enough to lead to quadriparesis as in our case. The pathognomonic skin manifestations are Gottron's papules (slightly elevated violaceous, papules located over the dorsal side of the metacarpal or interphalangeal joints), heliotrope rash (Lilac-purple rash on eyelids, often with edema), erythematous rash over the neck (V sign), shoulders and back (shawl sign), hip (holster sign). All these skin signs were lacking in our patients.^{3,4} Dermatomyositis specifically appears to have increased incidence of malignant conditions especially in elderly in 30%.⁴ The most common tumors associated are ovarian cancer, breast cancer, melanoma, colon cancer, and non-Hodgkin lymphoma. In dermatomyositis the endomysial inflammation is predominantly perivascular. The muscle fibers undergo necrosis, degeneration, and phagocytosis due to microinfarcts within the muscle which results in perifascicular atrophy, the diagnostic even in the absence of inflammation.^{3,4}

Conclusion

In the absence of characteristic skin manifestations and elderly patient presenting only as quadriparesis, high index of clinical suspicion is required for early diagnosis and management.

Conflict of Interest: None.

References

1. Marvi U, Chung L, Fiorentino DF: Clinical presentation and evaluation of dermatomyositis. *Indian J Dermatol* 2012;57(5):375-81.
2. Koler RA, Montemarano A. Dermatomyositis. *Am Fam Physician* 2001;64:1565-72.
3. Kalyan M, Kanitkar SA, Gaikwad AN, Kumar H. Dermatomyositis: A case report. *J Mahatma Gandhi Inst Med Sci* 2016;21:53-5.
4. Greenberg SA, Amato AA. Inflammatory myopathy. In: Jameson JL, Kasper DL, Longo DL, Fauci AS, Hauser SL, Loscalzo J, et al., editors. *Harrison's Principles of Internal Medicine*. 20 th ed. Vol. 2.: McGraw-Hill; 2019;2592.

How to cite this article: Garikapati A, Kumar S, Godhiwala P, Somani A, Nayak A. Severe dermatomyositis presenting as quadriparesis: An unusual sequel in elderly. *Ann Geriatrics Educ Med Sci* 2019;6(1):11-2.