

## Syndrome of inappropriate secretion of antidiuretic hormone (SIADH) induced by squamous cell carcinoma of larynx: A case report

Aman<sup>1</sup>, Ashiya Goel<sup>2</sup>, Vikasdeep Gupta<sup>3,\*</sup>, Jai Prakash Narayan<sup>4</sup>, Prikshit Manchanda<sup>5</sup>

<sup>1,2,4,5</sup>Junior Resident, <sup>3</sup>Senior Resident, Dept. of ENT, <sup>3-5</sup>Post graduate Institute of Medical Sciences, Rohtak, Haryana, India

**\*Corresponding Author:**  
Email: vdgupta88@gmail.com

### Abstract

Syndrome of inappropriate antidiuretic hormone secretion (SIADH) is one of the most frequent paraneoplastic syndrome associated with hyponatremia in patients with tumours. The most common malignancy associated with SIADH is small cell tumour of lung. Association of SIADH with head and neck malignancies is only seen in 1.5% of cases. We are reporting a case of 70 year old male, who came to emergency with irritable behaviour and stridor. On indirect laryngoscopy, there was proliferating mass right vocal cord. Emergency tracheostomy was done. Even though the blood pressure and pulse were within normal limits, patient was irritable and semiconscious. His serum sodium level was 110 mg/dl. Patient was started on fluid restriction and 3% saline infusion. On biopsy of mass right vocal cord, it was squamous cell carcinoma.

**Keyword:** Antidiuretic, Carcinoma.

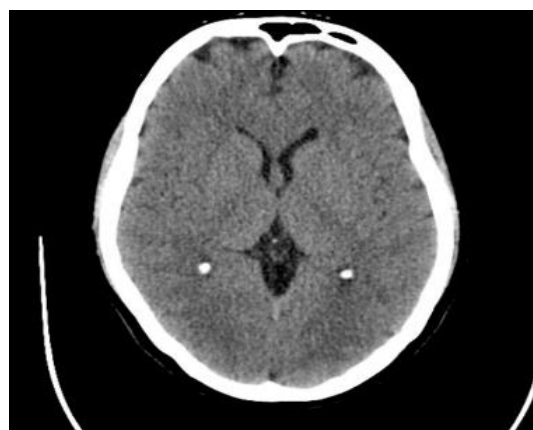Syndrome of inappropriate antidiuretic hormone secretion (SIADH) is most frequent paraneoplastic syndrome associated with hyponatremia with tumours. The most common malignancy associated with SIADH is small cell tumour of lung. SIADH is also associated with prostatic carcinoma, bladder carcinoma, mesothelioma, lymphomas, Hodgkin's disease, acute myelogenous leukemia, thymoma, small cell carcinoma of the esophagus and adrenocortical carcinoma.<sup>1</sup> Association of SIADH with head and neck malignancies is only 1.5%.<sup>2</sup> Hyponatremia is one of the most common electrolyte anomaly associated with tumours. It may be associated with life threatening neurological complications. It is graded into mild (serum sodium less than 135 meq/l), moderate (serum sodium less than 132 meq/l), severe (less than 130 meq/l and life threatening (serum sodium less than 125 meq/l or associated clinical symptoms).<sup>3</sup> Clinical symptoms of hyponatremia varies from fatigue, anorexia and lethargy to severe neurological manifestations like convulsions and coma. However, most patients are asymptomatic.<sup>4</sup> In this case report, we are reporting a case of squamous cell carcinoma of glottis associated with SIADH.

### Case Report

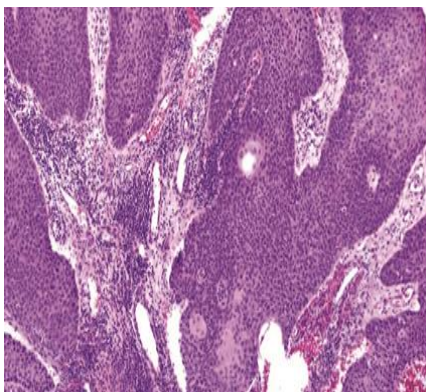
A 70 year old male was brought to emergency department with severe stridor associated with irritable behaviour. On indirect laryngoscopy, there was proliferative mass over right vocal cord obscuring the chink. Emergency tracheostomy was done. Airway was secured with 7.5 mm cuffed tracheostomy tube. Oxygen saturation came to 96% on room air. Blood pressure and pulse were within normal limits, still patient was irritable and disoriented. Serum electrolytes were sent along with blood gas analysis which yielded mild respiratory acidosis with serum sodium 110 meq/l.

Serum osmolality was 236 mosmO/l, urine osmolality was 350 mosmO/l, urine sodium concentration was 72 meq/l, serum urea concentration was 18mg/dl and serum uric acid concentration was 3.6 mg/dl. Thyroid profile and adrenal function tests were normal. NCCT head showed no intracranial anomalies. 3% saline infusion was started and serum sodium monitoring was done 6 hourly to monitor adequate response and osmotic demyelination syndrome. Fluid intake was restricted to 1000 cc per day. Serum sodium level improved for 3 days with improvement in clinical signs. There was dip in serum sodium level on 4<sup>th</sup> day. It improved again after 4<sup>th</sup> day. Serum sodium level became 136meq/l after 7 days.

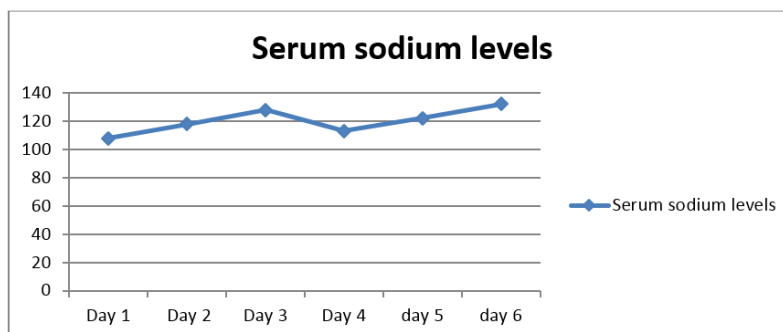
Diagnostic laryngoscopy with biopsy was done and on histopathological examination, it was squamous cell carcinoma moderately differentiated type. Patient underwent total laryngectomy with chemoradiation.



**Fig. 1: Normal NCCT Head**



**Fig. 2: Histopathological photograph of squamous cell carcinoma of larynx**



**Fig. 2: monitoring of serum sodium levels**

### Discussion

Association of SIADH with head & neck cancers is 1.5%.<sup>2</sup> The most common site of occurrence in head & neck region is oral cavity followed by larynx and nasopharynx. Other less frequent areas involved are the hypopharynx, the nasal cavity, the maxillary sinus, parapharyngeal space, salivary glands and oropharynx.<sup>5</sup> Schwartz et al. first described it in 1957 in bronchogenic small cell carcinoma.<sup>6</sup> In 1976, Moses et al. first described SIADH in patients with squamous cell carcinoma but they were unable to tell the mechanism behind it.<sup>7</sup> Kettler et al. described SIADH with oropharyngeal carcinoma on his research on 29 patients.<sup>8</sup>

SIADH may manifest before cancer presentation or after chemoradiation or surgery.<sup>9-11</sup> Diagnosis of SIADH should be considered in a patient with hyponatremia, (less than 135 mEq/L), urine osmolality greater than 100 mosm/Kg, serum osmolality less than 275 mosm/Kg, serum urea less than 30 mg/dl and serum uric acid less than 4mg/dl. Urinary sodium concentration is usually greater than 40 mEq/L. The absence of edema, orthostatic hypotension, dehydration and normal thyroid and adrenal function tests points towards SIADH.<sup>12</sup> In chronic nonendocrine SIADH, the relative hyperaldosteronism is observed due to the low sodium concentration, which stimulates directly aldosterone secretion by the adrenal gland.<sup>13</sup>

Management of hyponatremia requires finding out the exact cause of hyponatremia as management

depends upon the cause. SIADH causes euvolumic hyponatremia. In symptomatic hyponatremia, immediate hypertonic saline (3% NaCl) is infused. If history, physical examination and biochemical investigations indicate SIADH as most probable etiology for hyponatremia, fluid restriction (500–1000 mL daily depending on severity of hyponatremia) is the first step in treatment.<sup>14</sup> Six hourly serum sodium level monitoring is required initially to monitor appropriate response. The increase in serum sodium level must be less than 8-10 meq/l to avoid osmotic demyelination syndrome. Pharmacological therapy for SIADH includes use of demeclocycline, vaptans, and furosemide. Demeclocycline is a tetracycline derivative which induces nephrogenic diabetes insipidus, thus leading to increased serum sodium levels.<sup>15</sup> Vasopressin-2 receptor antagonist tolvaptan (15 mg/day) is also effective in stabilization of serum sodium levels in patients with SIADH.<sup>16</sup> Furosemide is often used in combination with salt tablets. It decreases reabsorption of sodium in Loop of Henle, thus causing diuresis and eventually slowly increasing serum sodium levels.<sup>17</sup>

### Conclusion

SIADH is the most common paraneoplastic syndrome in small cell lung carcinoma.<sup>1</sup> Its association with head and neck malignancies is only 1.5%.<sup>2</sup> It may precede diagnosis of head and neck malignancy or after induction of chemoradiation or surgery.<sup>9-11</sup> This case

illustrates the importance of the initial evaluation of hyponatremia and the need for effective data gathering in exploring the possible etiologies of hyponatremia. If hyponatremia is not responding to iv fluids for treatment of hyponatremia, the clinician should exclude other causes of hyponatremia like SIADH, dilution, edema states, hypertensive states, primary polydipsia, pseudohyponatremia, sick-cell syndrome, essential hyponatremia or side effect of several drugs. Our case is one of the few cases reported in literature for SIADH associated with squamous cell carcinoma of larynx.

## References

1. Ferlito A, Rinaldo A, Devaney KO. Syndrome of inappropriate antidiuretic hormone secretion associated with head and neck cancers: Review of the literature. *Ann Otol Rhinol Laryngol* 1997;106:878-83.
2. Y. Zohar, Y. P. Talmi, Y. Finkelstein, M. Nobel, and U. Gafer, Syndrome of inappropriate antidiuretic hormone secretion in cancer of the head and neck. *Ann Otol Rhinol Laryngol* 1991;100:341-44.
3. U.S. Food and Drug Administration. Center for Biologics Evaluation and Research. Toxicity grading scale for healthy adult and adolescent volunteers enrolled in preventive vaccine clinical trials. <http://www.fda.gov/cber/gdlns/toxvac.htm>. Accessed April 25, 2007.
4. Ellison DH, Berl T. The syndrome of inappropriate antidiuresis. *N Engl J Med* 2007;356:2064-72.
5. Sorensen JB, Andersen MK, Hansen HH. Syndrome of inappropriate secretion of antidiuretic hormone (SIADH) in malignant disease. *J Intern Med* 1995;238:97-110.
6. Schwartz WB, Bennett W, Curelop S, Bartter FC. A syndrome of renal sodium loss and hyponatremia probably resulting from inappropriate secretion of antidiuretic hormone. *J Am Soc Nephrol* 1957;12:2860-70.
7. Moses AM, Miller M, and Streeten HP. Pathophysiologic and pharmacologic alterations in the release and action of ADH. *Metabolism* 1976;25:697-721.
8. Ketteler M, Gross P, Menstell St, Weidauer H. Clinical significance of hyponatremia in patients with oropharyngeal carcinoma. *Laryngo Rhino Otologie* 1991;70:218-20.
9. Kusuki M, Igochi H, Nakamura A, Nishiura H, Kanazawa A, Yamane H. The syndrome of inappropriate antidiuretic hormone secretion associated with chemotherapy for hypopharyngeal cancer. *Acta Otolaryngol Suppl* 2004;554:74-7.
10. Berghmans T. Hyponatremia related to medical anticancer treatment. *Support Care Cancer* 1996;4:341-50.
11. Zacay G, Bedrin L, Horowitz Z, Peleg M, Yahalom R, Kronenberg J, Taicher S, Talmi YP. Syndrome of inappropriate antidiuretic hormone of arginine vasopressin secretion in patients following neck dissection. *Laryngoscope* 2002;112: 2020-24.
12. Liamis G, Mitrogianni Z, Liberopoulos EN, Tsimihodimos V, Elisaf M. Electrolyte disturbances in patients with hyponatremia. *Intern Med* 2007;46:685- 90.
13. Schneider EG, Taylor RE, Radke KJ, Dairs PH. Effect of sodium concentration on aldosterone secretion by isolated perfused canine adrenal glands. *Endocrinol* 1985;115:2195-204.
14. Furst H, Hallows KR, Post et al. The urine/plasma electrolyte ratio: a predictive guide to water restriction. *Am J Med Sci* 2000;319:240-44.
15. Sherlock M, Thompson CJ. The syndrome of inappropriate antidiuretic hormone: current and future management options. *Eur J Endocrinol* 2010;162:13-8.
16. Petereit C, Zaba O, Teber I, Lüders H, Grohé C. A rapid and efficient way to manage hyponatremia in patients with SIADH and small cell lung cancer: treatment with tolvaptan. *BMC Pulmonary Med* 2013;13.
17. Decaux G, Waterlot Y, Genette F, Hallemans R, Demanet JC. Inappropriate secretion of antidiuretic hormone treated with frusemide. *Br Med J* 1982;285:89-90.

**How to cite this article:** Aman, Goel A, Gupta V, Narayan J. P, Manchanda P. Syndrome of inappropriate secretion of antidiuretic hormone (SIADH) induced by squamous cell carcinoma of larynx: A case report. *Ann Geriatrics Educ Med Sci.* 2018;5(2):74-76.