

Rare case of gastric lymphoma

P. P. Dhakshayani^{1*}, S. Umarani², M. Ahila Muthu Selvi³

¹Professor & HOD, ²Associate Professor, ³Assistant Professor, Dept. of Geriatric Surgery, Rajiv Gandhi Government General Hospital, Chennai, Tamil Nadu, India

***Corresponding Author:**

Email: gersurmmc@gmail.com

Abstract

Gastric lymphoma is an RARE disease, may either represent primary malignancy confined to stomach or secondary involvement by systemic disease. Herin, we report a case of gastric lymphoma in a 63 years old male patient presenting with symptoms of upper abdominal pain , melena, vomiting ,loss of appetite for period of 6 months.

Keyword: Gastric lymphoma, Mucosa-associated lymphoid tissue.

Introduction

Gastric lymphoma represents the most common site of extra nodal lymphoma, accounting for 25% of all such lymphomas, 50% of all gastro intestinal lymphomas, but comprise only 1-5% of all gastric malignancies. Typically primary gastric lymphoma occurs in adults in the 6th decade of life and the presentation is no different from gastric cancer.

Case Report

63 years old male got admitted with complaints of upper abdominal pain, melena, vomiting, loss of appetite for 6 months. On examination patient anaemic, vague epigastric mass, which moves with respiration, no ascitis.

Investigation done blood Hb 7.9gms liver function test normal, CECT Abdomen and pelvis shows Multiple para aortic and pericaval nodes, suggests d biopsy to exclude infection versus neoplastic process like lymphoma.

Upper GI scopy done .Biopsy taken –report came as Adenocarcinoma. 8 units of blood transfusion done.

So patient was prepared for surgery. Subtotal gastrectomy done. Intra operative finding –no ascitis, liver normal, multiple celiac nodes seen, growth stomach occupying antropyloric region extending to body and lesser curvature of stomach. Stomach bed free, so proceed with subtotal gastrectomy with gastro jejunostomy done.

Biopsy report –Subtotal gastrectomy specimen shows mucosal ulceration and diffuse infiltrating growth measuring 12x11x15 cm growth infiltrating into muscle layer and serosal layer. Microscopy report –Gastric mucosa with superficial erosion and necroinflammatory exudates underlying submucosa showing neoplastic arranged diffuse sheets composed of monotonous population of small round cells with scanty cytoplasm and vesicular nucleoli showing prominent nucleoli intervening stroma shows few congested blood vessels admixed with plasma cells. Suggestive of lymphoma, poorly differentiated carcinoma

stomach. So we did IHC for this specimen came as Non Hodgkins Lymphoma B cell type. After surgery patient sent for medical oncologist opinion, their opinion was Non Hodgkin lymphoma affecting stomach (isolated involvement of stomach –likely). So CECT –neck, thorax, bone marrow study –not needed, patient was started on CHOP regimen. Now patient is on chemotherapy. Patient is well responding to chemotherapy.

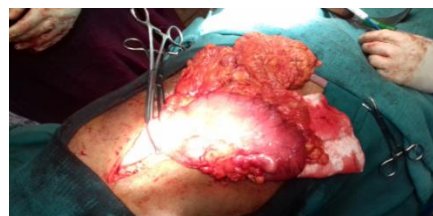

Fig. 1: Intra Operative Picture

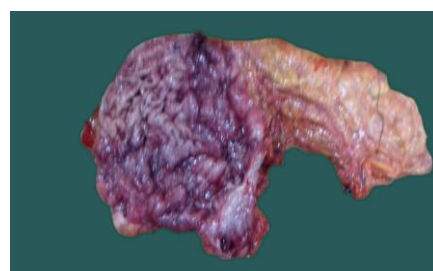

Fig. 2: Specimen

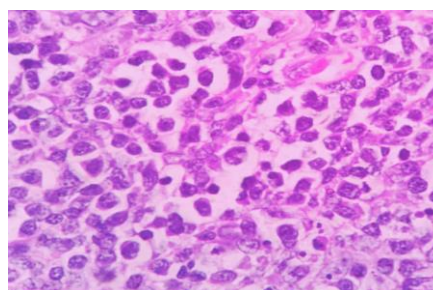


Fig. 3: Histopathology picture of Gastric lymphoma

Discussion

Gastric lymphoma is the most common in the sixth decade, the common symptoms being pain, weight loss and bleeding. Three types of gastric lymphoma are recognized 1. Low grade MALT lymphoma: 60% of all primary gastric lymphoma 2. Primary sporadic lymphoma: the vast majority are B- cell non Hodgkins lymphoma 3. Secondary involvement of the stomach by systemic lymphoma (usually high grade)

Mucosa-associated lymphoid tissue (MALT) lymphoma is strongly associated with *Helicobacter pylori* (85-98% of cases). These are low grade lymphomas and may regress following the treatment of helicobacter infection.

Primary gastric lymphoma remains in the stomach for a prolonged period before involving the lymphnodes. At an early stage, the disease takes the form of diffuse mucosal thickening, which may ulcerate.

Diagnosis is made as a result of endoscopic biopsy. Adequate staging is necessary, primarily to establish whether the lesion is a primary gastric lymphoma or a part of a more generalized process. CT scan of the

Chest, Abdomen and bone marrow aspirate are required, as well as a full blood count.

Radiographic features

Fluoroscopy: barium meal- Appearances vary from normal, to grossly abnormal possible appearances include bull's eye appearance due to central ulceration , filling defects , thickened gastric rugae , linitis plastic.

CT findings: Typically gastric lymphoma demonstrates marked thickening of the stomach wall with a large lateral extension of the tumour (i.e. along the wall of the stomach) representing submucosal spread. In some instances the submucosal spread encompasses the majority of the stomach, giving it a linitis plastic appearance. Extensive retroperitoneal and local nodal enlargement is often seen.

The treatment of primary gastric lymphoma is surgery alone in a case of localized disease process, although some oncologist contend that primary gastric lymphoma can be treated by chemotherapy alone. Chemotherapy alone is appropriate for patient with systemic disease. Early gastric lymphomas may regress and disappear when the *Helicobacter* infection is treated.

The two common complications are bleeding and perforation.

Table 1: Staging of gastric lymphoma

Stage	Lugano staging system	Tnm staging system (modified for gastric lymphoma)	Anna arbor staging system	Tumor involvement
I	Confined to GI tract (single primary or multiple, noncontiguous)	T1 NO MO T2 NO MO T3 NO MO	Ig Ig Ig	Mucosa, submucosa Muscularis propria Serosa
II	Extending into abdomen II a – local nodal involvement IIb - Distant nodal involvement	T1-3 N1 Mo T1-3 N2 MO	IIg IIg	Perigastric or peri-intestinal lymph nodes More distance regional lymph nodes
III	Penetration of serosa to involve adjacent organs or tissue	T4 NO MO	Ig	Invasions of adjacent structures
IV	Disseminated extra nodal involvement or concomitant supra diaphragmatic nodal involvement	T1- 4 N3 MO T1 – 4 N0-3 M1	IIIg IVg	Lymph node on both side of the diaphragm Distant metastases (e.g bone marrow or additional extra nodal sites)

Conclusion

Gastric lymphoma is an interesting disease, unlike gastric carcinoma, the lymphoma seems to be increasing. These patients are having a very good response when treated with surgery and chemotherapy.

References

1. Dawson IM, Cornes JS, Morson BC (July 1961). "Primary malignant lymphoid tumours of the intestinal tract. Report of 37 cases with a study of factors influencing prognosis". *Br J Surg.* 49:80–9. doi:10.1002/bjs.18004921319. PMID 13884035.
2. Aisenberg AC (October 1995). "Coherent view of non-Hodgkin's lymphoma". *J. Clin. Oncol.* 13 (10):2656–75. PMID 7595720.
3. Koch P, del Valle F, Berdel WE, et al. (September 2001). "Primary gastrointestinal non-Hodgkin's lymphoma: I. Anatomic and histologic distribution, clinical features, and survival data of 371 patients registered in the German Multicenter Study GIT NHL 01/92". *J. Clin. Oncol.* 19(18):3861–73. PMID 11559724.
4. Thirlby RC (January 1993). "Gastrointestinal lymphoma: a surgical perspective". *Oncology (Williston Park, N.Y.)*. 7 (1): 29–32, 34; discussion 34,37–8. PMID 8420540.

5. Parsonnet J, Hansen S, Rodriguez L, et al. (May 1994). "Helicobacter pylori infection and gastric lymphoma". *N. Engl. J. Med.* 330 (18):1267–71. doi:10.1056/NEJM199405053301803. PMID 8145781.
6. Bayerdörffer E, Neubauer A, Rudolph B, et al. (June 1995). "Regression of primary gastric lymphoma of mucosa-associated lymphoid tissue type after cure of Helicobacter pylori infection. MALT Lymphoma Study Group". *Lancet.* 345 (8965):1591–4. doi:10.1016/S0140-6736(95)90113-2. PMID 7783535.
7. Hammel P, Haioun C, Chaumette MT, et al. (October 1995). "Efficacy of single-agent chemotherapy in low-grade B-cell mucosa-associated lymphoid tissue lymphoma with prominent gastric expression". *J. Clin. Oncol.* 13 (10):2524–9. PMID 7595703.