



Case Report

A case report of the Exostosis of ear of an elderly female: Successful healing with Integrated Yoga Prana Vidya (YPV) healing approach as alternative to surgical intervention

Kokil Gupta¹, Venkata Satyanarayana Nanduri^{1,*}

¹YPV Ashram, Sri Ramana Trust, Thally, Tamil Nadu, India



ARTICLE INFO

Article history:

Received 16-11-2019

Accepted 20-11-2019

Available online 26-12-2019

Keywords:

Ear diseases

Exostosis

Canaloplasty

Multiple ailments

Treatment

Yoga Prana Vidya healing

ABSTRACT

Introduction: Exostosis of the external auditory canal is a relatively rare lesion but is the commonest tumor of the bony external ear. Canaloplasty alone is the surgical treatment of choice for exostoses and other lesions of the external auditory canal. This case study presents how a patient with Exostosis was fully healed using Yoga Prana Vidya Healing system without need of surgical intervention.

Materials and Methods: This is a case study method, going through full detailed records of a 64 year old female patient diagnosed as having Exostosis, health conditions pre and post treatments using YPV healing system observed through ear specialist's reports, as well as data collected from follow-up interviews of the subject.

Results: Analysis of this case shows positive results of improvement without surgery obtained with use of YPV healing methods by healers and also some self-healing techniques practiced by the patient, enabling her to have normal hearing and overall health.

Conclusions: This case study documents the evidence gathered on the effective use of YPV in healing and treating Exostosis condition, besides healing some other ailments of the patient holistically. To produce holistic and optimum results, YPV uses a combination of approaches such as, (1) physical exercises including rhythmic yogic breathing, (2) Salt free diet; fruit diet, (3) Meditation techniques, (4) healing by trained and experienced healers, patient participation in group healing, self-healing by patients with regular self-practice of some specified techniques. There is ample scope to conduct further research on the application of YPV as alternative, effective and low cost medicine for various other medical conditions.

© 2019 Published by Innovative Publication. This is an open access article under the CC BY-NC-ND license (<https://creativecommons.org/licenses/by/4.0/>)

1. Introduction

External auditory canal exostoses are the most common benign tumors of the external auditory canal, and their pathology is attributed to hyperostosis of the temporal bone.¹ Exostosis of the external auditory canal is a relatively rare lesion but is the commonest tumor of the bony external ear. It results from benign hyperplasia of the lamellar bone secondary to chronic thermal, physical, or chemical trauma. In the pre-antibiotic era, chronic aural infection was the most common cause of Exostosis. In the present day scenario, chronic exposure to cold sea water,

in activities such as surfing, swimming, and diving, is the most common cause of Exostosis, and hence, the condition has been called the “surfer's ear.” Most patients present with unilateral hearing loss, pain, and tinnitus due to impacted cerumen secondary to the narrowing of the lumen of the external auditory meatus, although radiologically, findings are almost always bilateral.² In modern medicine, Canaloplasty alone is the treatment of choice for exostoses and other lesions of the external auditory canal.

Canaloplasty is a procedure to widen the external auditory canal usually posteriorly and superiorly by removing all overhangs lateral to tympanic annulus as to become an inverted cone, while meatoplasty is widening of the auditory meatus for aeration to mastoid cavity. It

* Corresponding author.

E-mail address: vsnanduri@yahoo.com (V. S. Nanduri).

is performed in Exostosis resulting in cholesteatoma of external auditory canal and retention of cerumen. Bone is removed from posterior and superior bony auditory canal along with conchal cartilage. Canaloplasty is a part of repair in congenital aural atresia, or otoplasty with the widening of surgical horizon of otolaryngologist to head and neck surgeon and plastic surgeon. The secret of success of this procedure is in preservation of canal skin and to do so, canal is widened in parts.³ It is therefore advisable to use alternative and effective non-surgical treatment method with low cost to treat Exostosis is.

It has been observed that Yoga Prana Vidya (YPV) which is a non-touch non-drug bio-energy healing method has been used successfully to heal patients having diabetes and difficult and multiple medical conditions.^{4,5} This paper presents one case study in which Exostosis was successfully healed by YPV without need of surgical intervention.

Yoga Prana Vidya

According to the founder of Yoga Prana Vidya (Yoga Prana Vidya Research, 2019),⁶ the concept of Yoga has to be understood in a broader and in a deeper sense. Yoga in recent times is used to refer to asanas (Postures) and sometimes even to pranayama (a form of breathing). These are parts of yoga and not completely yoga. If viewed from the yogi Patanjali point of view, it is known as Ashtang (eight parts) Yoga. There are many levels of yoga in practice and yoga means all of this. Each of the steps is very important. It is the soul using this physical body but the body is an important vehicle of the soul. This vehicle is so important in the physical world to be maintained, sustained and used for the purpose of the Divine. The purpose of yoga is to achieve union and manifest greatness on earth. The incarnated soul or Jeevatma has 3 vehicles.

1. The physical body including energy body is called the Pranamaya kosha
2. Above that is The Emotional body which is called Kama kosha
3. Above that is The Mental body, the Manomaya kosha

To maintain our physical body it involves maintaining the energy body, because energy body is the basic mould of the physical body, which science now recognizes as a bio-Plasmic body. Anything that happens in the physical body, has its effect on the etheric body and vice versa. This etheric body is referred to as “ etheric double ” in theosophy. Any ailment in the physical body has its effect on the etheric body. So we use the term Prana Vidya. Prana is Life Force or Energy used for the maintenance of the energy body and Vidya is basically the technology of how to do so. The technology of maintaining the energy body is Yoga Prana Vidya. Thus YPV offers proven techniques for maintaining the physical and energy body and also maintain the etheric connectivity with the higher self which involves meditations.

Healing is the process by which the energy body can be renewed thus bringing change in the physical body, because the former interpenetrates the latter. Used up energy or diseased energy can be removed and the energy body can be impregnated with fresh energy. All biological life on earth has the ability to heal itself. Energy follows thought and energy accelerates the healing process. So the energy is used in healing to accelerate the healing process and the body heals itself.

Healing consists of two processes.

1. Cleansing: removal of the used-up energy
2. Energizing: giving fresh energy.

In YPV, healer becomes a channel of energy who receives and transfers energy. Yoga Prana Vidya (YPV) is a revolutionary form of energy “medicine”. It is an ancient science and art that has been revived in a new form which is easily adaptable and in tune with modern day busy life. The air around us contains a special life force that keeps us alive. This life force is also known as “prana” (“Breath of Life”). YPV reveals various techniques of using prana in order to better and promote good health. Yoga Prana Vidya has been used as a tool to deal with psychological and emotional issues also to remedy everyday work and financial stresses of life. It is primarily used as a non-touch, drugless healing system, complementary (along with) to other healing modalities like Allopathy, Ayurveda, and Homeopathy. However, there are numerous instances where the application of YPV healing alone has been sufficient to alleviate the ailment/ disease (both physical and psychological).

2. Case Report

2.1. Patient Background

A 64 year old female, house wife and a YPV practitioner, visited an ENT care clinician on 20 March 2019 in Delhi with complaint of discharge in left ear, for which she was taking medication under treatment for the previous 3 months from another doctor in another part of India where she was temporarily residing. She did not have any significant relief from this treatment.

2.2. Diagnosis by ENT clinician

On examination, patient’s left ear was full of purulent discharge (see document in Figure 1). She was diagnosed as CSOM (Chronic suppurative otitis media) and systematic antibiotic and other medications (see Figure 3) were advised for 7days. Repeat ENT examination was done On 28 March 2019 and it was seen that discharge had stopped but whitish /pearlish mass was seen and a collection of creamy pus was suspected, and a perforation of Tympanic Membrane was seen. Suction clearance was tried but it did not change

status and nothing could be sucked. So, foreign body/cotton was suspected and syringing done. There was a hole on the ear drum. Only dry flakes came and whitish /pearlish mass was at its place. Then the patient was referred to specialist ENT surgeon who diagnosed the condition as Exostosis and advised surgical removal under LA (Figure 1).

2.3. Patient's Perspective and Choices

“From December 2018 I had infection in my left ear, I was in South India at that time. I was on antibiotics for some time to get some relief from the pain, but the relief was only temporary. I had many sleepless nights due to the unbearable pain. On 20th March 2019, I came back to Delhi and went to my family doctor who diagnosed that the left ear was severely infected and full of puss. I was put on a few medicines for a few days (Figure 3). I revisited the doctor again on 28/3/2019 after completing the medicinal course for a review. He suspected that there was something pearlsh stuck in my left ear he tried ways and means to clean the ear canal but that pearlsh mass was on its place only. Doctor also told that there is a small hole in the eardrum, he advised me to consult senior ENT Surgeon whom I consulted on the same day. He diagnosed EXOSTOSIS in left ear and suggested to remove this through surgery (Figures 4 and 5). I asked the doctor how urgent is the surgery required to be done for which he answered that you can take a few weeks. At that stage, I was reluctant to go through the surgery and asked one senior YPV healer to start healing for my EXOSTOSIS of the left ear.”

2.4. YPV Healing Intervention

Integrated YPV healing approach was used in this case of EXOSTOSIS consisting of rapidly increasing the natural healing ability of the body to heal itself, and the steps stated below were followed to bring about improvements in the patient

1. Physical exercises including breathing
2. Rhythmic yogic breathing exercise
3. Diet (salt free and fruit)
4. Planetary Peace Meditation
5. Forgiveness
6. Energy Healing

Steps 1-5 stated above were self-practiced by the patient. YPV Healing technique at Step 6 was performed by the healer. YPV Healing involved balancing of energy body and chakrams, which have both physical and psychological functions. It has processes of cleansing and energizing the affected parts and chakrams.

1. YPV Psychological healing
2. Physical healing: YPV techniques for healing the energy body and Chakrams resulting in physical

healing. In each individual healing, first psychological healing is done followed by healing of energy body for healing the physical body.

- General Cleansing - cleaning of aura
- Cleansing the blood and strengthening technique
- Rapidly cleansing the internal organs
- Cleaning and energizing the affected part of the left ear (Exostosis) and the connected ear minor chakrams.
- How healing sessions were conducted:

Healing was given from a distance. Follow up and feedback taken after every 2 weeks for two and a half months. Total duration of interventional healings was two and a half months (three weeks daily and then twice a week). Total number of healings given in this duration was 35 healings

2.5. Patient medical status post- YPV Healing

Patient was again reviewed by the ENT Clinician on 13 June 2019 and no growth/mass was seen, and perforation had healed (Figure 2). Ear was dry. Tympanic membrane were normal. Patient reported to this clinician that no surgical/medical treatment was taken by her. On examination, no surgical scar was seen. Clinician noted that according to the patient, she has taken YPV system of healing for this ailment. Clinician observed that no possible explanation could be given for spontaneous resolution/self-Healing of Exostosis as diagnosed by ENT surgeon. The ENT surgeon also examined the patient on 18 June 2019 and observed that her both ears were normal (Figure 6). He confirmed (see Figure 7) that Exostosis in the ear was no longer present, and he was eager to know more about YPV system.

2.6. Patient feedback after healing

“I was completely healed, 70% from pain in the first week since the commencement of healing, after 4 weeks we again visited the Doctor. I was amazed as well as astonished to find that EXOSTOSIS reduced in size by 60 – 70 % and only approximately 40 % was left and eardrum was much visible now, and some perforation was seen in the eardrum. We were advised to review after a month, I was relaxed and confident that it would be dissolved completely without any surgery. I continued PPM, yogic breathing and forgiveness Sadhana totally, while healing was continued by the senior healer. I Visited ENT surgeon after one and a half month for a review. The surgeon confirmed that there was no EXOSTOSIS in my left ear and also the hole in ear drum disappeared. I told them that it is treated through YPV system of energy healing without any surgical intervention.”

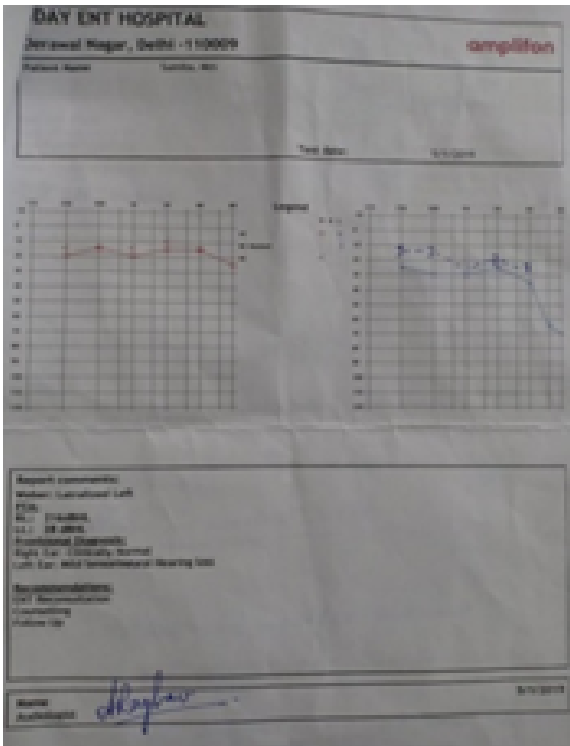


Fig. 5: Sound test

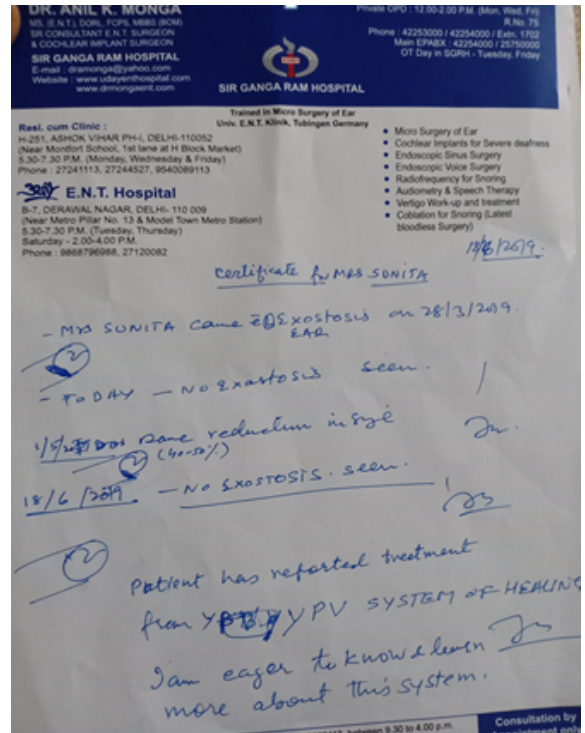


Fig. 7: Final Discharge certificate showing “ No Exostosis seen ”

3. Discussion

It is observed in this case report that, in contrast to the surgical procedure to remove Exostosis, YPV Healing which is a non-invasive process fully treated the condition bringing relief to the patient. Otherwise, the surgery would have been very costly and painful for the patient, and this YPV Healing enabled saving cost to the patient and his family. YPV Healing is a non-invasive and non-touch, no-drug system which is observed to be effective for a receptive patient in treatment of this ailment through the evidence shown. In most cases of YPV healing, the patients get empowered to maintain themselves subsequently. Many of them even learn and become effective healers themselves.

4. Conclusion

This case report documents the evidence gathered on the effective use of YPV in healing ear ailment diagnosed as Exostosis, which otherwise needed a surgical procedure. The general conditions under which YPV produces optimum results holistically is also derived from the fact that YPV uses a combination of approaches, (1) physical exercises including rhythmic yogic breathing, (2) Salt free diet; fruit diet, and (3) Meditation techniques, healing by healers, group healing, self-healing by patients, and regular self-practice by patients. These patients have also become trained healers, practice healing and act as role model for other people with several ailments seeking alternative

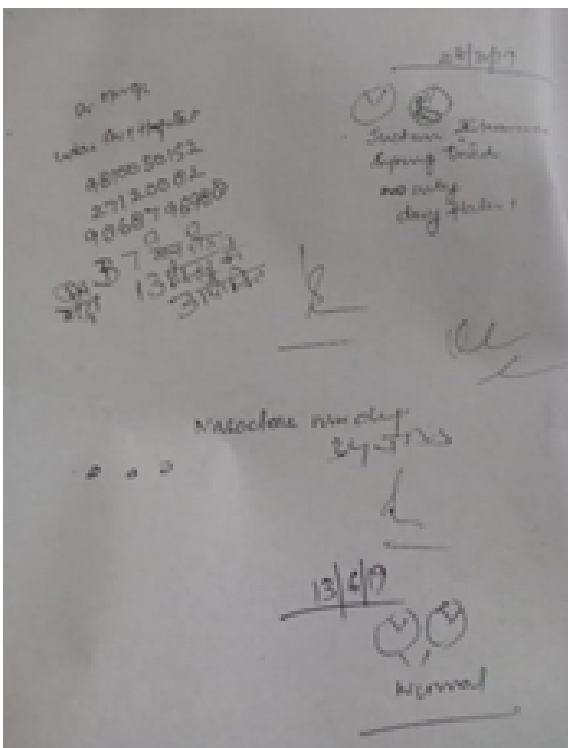


Fig. 6: Surgeon assessment

effective medicine. YPV helps as preventive medicine also, when the seekers are receptive and undertake regular practices of the self-practice techniques of YPV such as exercises, Rhythmic breathing, meditation and salt-free controlled diet.

4.1. Acknowledgements

The authors express sincere thanks to Sri Ramana Trust for giving permission to use their copyright terms, Yoga Prana VidyaTM and YPV[©], and also for allowing them to use the patient medical reports and data in this report.

5. Source of Funding

None.

6. Conflict of Interest

None.

References

- Hirose Y, Shikino K, Ikusaka M. Surfers ear and external auditory canal exostoses. *QJM: An Int J Med.* 2016;109(11):759.
- Patwari SS, Joshi S, Chadaga HC. Bilateral exostosis of the external auditory canal: Surfer's ear. *Neurol India.* 2019;66:1520–1521. Available from: <http://www.neurologyindia.com/text.asp?2018/66/5/1520/241360>.
- Taneja MK. Role of Canaloplasty: Editorial. *Indian J Otolaryngology.* 2013;19:159–163.
- Diabetes Management and Control Using Yoga Prana Vidya (YPV) Healing System. *J Biol Life Sci.* 2019;10(2):106–120.
- A study into successful treatment of some difficult Medical cases using Yoga Prana Vidya (YPV) Healing System as alternative medicine. *Int J Scientific Engineering Res.* 2019;10(7):882–887.
- A compendium of Theory, Research and practice of Yoga Prana Vidya. Unpublished document, YPV Ashram. Sri Ramana Trust, Thally, Tamilnadu, India ; 2019..

Author biography

Kokil Gupta Senior Arhatic

Venkata Satyanarayana Nanduri Consultant, Research and Publications

Cite this article: Gupta K, Nanduri VS. A case report of the Exostosis of ear of an elderly female: Successful healing with Integrated Yoga Prana Vidya (YPV) healing approach as alternative to surgical intervention. *Ann Geriatrics Educ Med Sci* 2019;6(2):42-47.